

# Phototherapy Promotes Healing of Chronic Diabetic Leg Ulcers That Failed to Respond to Other Therapies

Debora G. Minatel, PT, PhD,<sup>1,2</sup> Marco Andrey C. Frade, MD, PhD,<sup>3</sup>  
 Suzelei C. França, PhD,<sup>1</sup> and Chukuka S. Enwemeka, PhD, FACSM<sup>4\*</sup>

<sup>1</sup>Department of Biotechnology, University of Ribeirão Preto, Ribeirão Preto, Brazil

<sup>2</sup>Department of Biotechnology, Federal University of the Amazon, Manaus, Brazil

<sup>3</sup>Division of Dermatology, Internal Medicine Department and School Health Center, Faculty of Medicine of Ribeirão Preto, University of São Paulo, Ribeirão Preto, Brazil

<sup>4</sup>School of Health Professions, Behavioral and Life Sciences, New York Institute of Technology, Old Westbury, New York

**Objective:** We tested the hypothesis that combined 660 and 890 nm LED phototherapy will promote healing of diabetic ulcers that failed to respond to other forms of treatment.

**Research Design and Methods:** A double-blind randomized placebo controlled design was used to study 23 diabetic leg ulcers in two groups of 14 patients. Group one ulcers were cleaned, dressed with 1% silver sulfadiazine cream and treated with “placebo” phototherapy ( $<1.0 \text{ J cm}^{-2}$ ) twice per week, using a Dynatron Solaris 705<sup>®</sup> device. Group two ulcers were treated similarly but received  $3 \text{ J cm}^{-2}$  dose.

**Results:** At each of 15, 30, 45, 60, 75, and 90 days of healing, mean ulcer granulation and healing rates were significantly higher for group two than the “placebo” group ( $P < 0.02$ ). While “placebo” treated ulcers worsened during the initial 30 days, group two ulcers healed rapidly; achieving 56% more granulation and 79.2% faster healing by day 30, and maintaining similarly higher rates of granulation and healing over the “placebo” group all through. By day 90, 58.3% of group two ulcers had healed fully and 75% had achieved 90–100% healing. In contrast, only one “placebo” treated ulcer healed fully by day 90; no other ulcer attained  $\geq 90\%$  healing.

**Conclusion:** Combined 660 and 890 nm light promotes rapid granulation and healing of diabetic ulcers that failed to respond to other forms of treatment. *Lasers Surg. Med.* 41:433–441, 2009. © 2009 Wiley-Liss, Inc.

**Key words:** diabetes; leg ulcers; phototherapy; biostimulation

## INTRODUCTION

Evidence abounds that treatment with polychromatic or monochromatic light (phototherapy), in particular light and/or infrared radiation with less than  $200 \text{ mW-cm}^{-2}$  irradiance and 600–1,000 nm wavelength [1–2], promotes the repair processes of skin [3–12], ligament [13–16], tendon [17–20], bone [13,21–24], and cartilage [13,25–29] in experimental animal wounds and human ulcers of various etiologies [30–33]. There is evidence that phototherapy advances tissue repair by promoting fibroblast proliferation [34–44], synthesis of collagen and other

components of tissue [45–48], and by enhancing the cellular and sub-cellular processes needed to enhance the formation of type I and type III procollagen pools of mRNA [49], ATP synthesis and lymphocytic action [5,50–51].

Other reports [52–59] suggest the contrary, prompting the prevailing skepticism about the value of phototherapy as a clinical armamentarium. For example, cultured human fibroblasts irradiated with 0.9 mW helium-neon laser over a 5-day period were neither stimulated nor inhibited in comparison with similarly handled control fibroblasts [58]. Likewise, rat skin incisions treated daily with 1, 2, or  $4 \text{ J cm}^{-2}$  of “He-Ne laser” did not heal faster than control incisions when calipers were used to measure their rates of contracture [59]. And after seven or 14 days of treating the incisions, the tensile strength of treated wounds did not differ from the strength of an untreated control group [59]. Furthermore, a clinical study of 58 teeth extraction patients who had one of two gingival flaps lased with  $0.34 \text{ J cm}^{-2}$  670 nm “diode laser” and the other left as untreated control produced mixed results. Whereas, clinical and photographic evidence showed that 69% of irradiated incisions healed faster than controls, in contrast, no significant differences in healing were observed when the patients were compared by age, gender, race, and anatomical location of injury [60].

In general, clinical studies showing that phototherapy promotes ulcer repair lack experimental controls [5]. The dearth of well-controlled clinical studies and the wide range of variables that must be considered and controlled in clinical practice—such as wavelength, power, power density, energy, energy density, treatment duration, treatment intervention time post-injury and contact versus non-contact methods of treatment—complicate the scenario. Nonetheless, clinicians continue to embrace phototherapy as a non-invasive, safe and comparatively

\*Correspondence to: Chukuka S. Enwemeka, PhD, FACSM, Professor and Dean, School of Health Professions, Behavioral and Life Sciences, New York Institute of Technology, Old Westbury, NY 11568-8000. E-mail: Enwemeka@nyit.edu

Accepted 18 May 2009

Published online in Wiley InterScience  
 (www.interscience.wiley.com).

DOI 10.1002/lsm.20789

inexpensive treatment with the potential to promote ulcer repair, minimize infection, and restore function in patients with healing resistant wounds; such as chronic diabetic ulcers that often occasion limb amputation.

In the United States alone, diagnosed and suspected cases of diabetes exceed twenty million—approximately 7% of the general population—15% of whom will undergo lower limb amputation because of chronic ulceration and circulatory complications [61]. More than one billion dollars is spent on chronic diabetic wounds every year. This estimate does not include lost labor, estimated at two million days per year [61]. There have been significant advances in ulcer care within the last 20 years, but to date, a cure for healing-resistant diabetic ulcers remains elusive. In recent times, interest has focused on the use of polypeptide growth factors to stimulate wound repair [62–64]. Whereas growth factors have been shown to promote healing of experimental wounds in animal models, their use in human cases of ulcers is relatively new, and results have been disappointing [64]. Moreover, costs are prohibitive and their potential side effects remain a major concern [64,65].

Finding a cure for healing-resistant leg ulcers associated with diabetes will be of immense benefit to society, because it will stem pain and suffering, prevent limb amputation, save costs and promote human productivity. Consequently, we determined the effect of a combination of red 660 nm and infra-red 890 nm light on healing of diabetic ulcers that failed to respond to other available forms of treatment. In this article, healing is operationally defined and measured as the rates of wound closure and re-granulation of the ulcers.

## METHODS

### Patients and Experimental Design

A double-blind completely randomized placebo controlled experimental design was used to study 14 patients with 23 chronic diabetic leg ulcers. Subjects were recruited mostly from the ulcer clinic of the Health School Center, Ribeirão Preto, and also from the Outpatient Neurovascular Leg Ulcer Clinic of the University Hospital, Faculty of Medicine Ribeirão Preto, University of São Paulo, São Paulo State, Brazil. Following approval of the research protocol by the Research Ethics Committee, University of Ribeirão Preto [Approval No. 131/06/COORD. CEP/CSE-FMRP-USP.15/3/2006], patients who met the following criteria were included in the study: (1) Diagnosis of type II diabetes independent of glycemic control with neuropathic or mixed (venous and arterial) ulcers, (2) Ulcer is located on the lower extremity, (3) Ulcer is present for a minimum of 4 weeks during which it has been either stable or worsening, (4) Willingness to participate in the study and commitment to the follow-up protocol; and (5) Signed written consent to participate in the study.

Patients with any of the following conditions were excluded from the study: (1) Evidence of local infection, acute cellulitis, osteomyelitis or gangrene anywhere in the affected extremity, (2) Presence of any of one or more

medical conditions including renal, hepatic, hematologic, neurologic, or immune disease which in the opinion of the co-principal investigator (MACF) constitutes a confounding variable, (3) Presence of malignant disease (other than basal cell carcinoma) not in remission for more than 5 years, (4) Use of oral or parenteral corticosteroids, immunosuppressive, or cytotoxic agents, (6) Known infection with HIV or presence of AIDS, and (7) Use of other investigational drug or device within 30 days of recruitment into the study. In additions, other leg ulcers, such as ulcers due to arterial insufficiency, decubiti, or vasculitis were excluded.

### Phototherapy Equipment

A Dynatron Solaris 705<sup>®</sup> phototherapy research device (Dynatronics Corporation, Salt Lake City, UT), customized to permit the use of two identical interchangeable applicators, labeled “Probe One” and “Probe Two” respectively, was used to treat the patients. Besides, the emission of a similarly colored red light, no other parameter of light produced by each probe was known to the investigators until the study was completed. The characteristics of the two probes revealed afterwards indicate the following: Probe Two was designed to emit light from thirty-two 890 nm superluminescent diodes (SLDs) and four 660 nm SLDs, making a total of 36 diodes interspersed in a 5 cm<sup>2</sup> cluster (Fig. 1). This probe, intended for real treatment, emitted 500 mW average power, yielding an irradiance of 100 mWcm<sup>-2</sup>. Probe one was designed as a placebo applicator. Because 660 nm light is visible red light, and the infrared 890 nm light; invisible infrared radiation, the 890 nm diodes in Probe One were disabled so that it produced just 660 nm light. To further reduce the amount of light emitted by this probe, the outer three diodes were also disabled and a resistor added to minimize the amount of

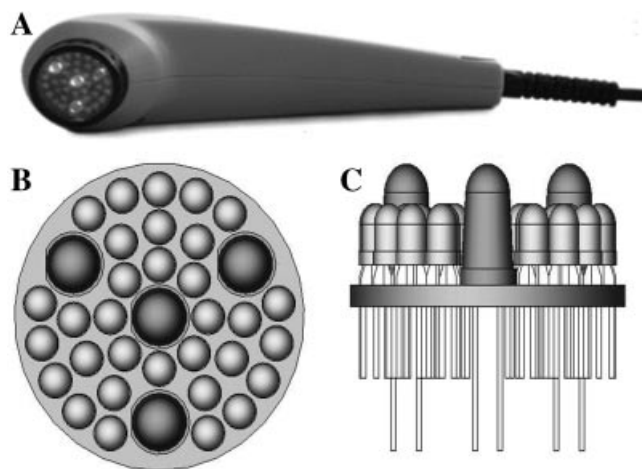


Fig. 1. Cluster of red 660 nm and infrared 890 nm light emitting diodes (LEDs) used for treatment. (A) shows a probe with 36 diodes; four red and 32 infrared. (B) shows the arrangement of the diodes in cross-section. The larger and darker diodes are red, while the infrared diodes are the smaller lighter ones. (C) is a horizontal view of the diodes.

light produced by the lone centrally located diode; making it produce less than 5 mW average power or  $<1 \text{ mW cm}^{-2}$  irradiance. Besides these well masked differences, the two probes were identical and could only be distinguished by their labels. Thus, neither the patients nor the research team knew which probe was placebo or real until the study was completed.

### Treatment

Patients were randomized and their ulcers treated either with Probe One or Probe Two until they healed fully or for a maximum of 90 days. Ulcers were cleaned with 0.9% physiological saline and then dried before phototherapy was applied twice per week. Thereafter, the ulcers were dressed with 1% silver sulfadiazine cream covered with gauze and bandaged. Given the  $100 \text{ mW cm}^{-2}$  irradiance of probe two, each spot size was treated for 30 seconds, yielding a fluence of  $3.0 \text{ J cm}^{-2}$ . Thus, larger ulcers required more time as treatment was applied in the contact mode sequentially from one spot size to another until the entire ulcer was completely treated. To avoid cross-contamination, each ulcer was covered with a clear transparent thin film of clear plastic (Pratic<sup>®</sup>), verified to transmit 100% light in our previous studies [66,67].

### Ulcer Measurement

Healing of each ulcer was evaluated by digital photography, using a Sony<sup>®</sup> DSC-P100. As detailed in our previous studies [66,67], the camera was custom fixed to an aluminum base with a 30 cm ruler attached perpendicularly to one end of the fixture. The fixture enabled standardized photography, making it easy for pictures to be taken vertically from a constant distance of 30 cm every week. Ulcer area and the area of granulation in each photograph were then measured using Image J<sup>®</sup> software (US National Institutes of Health, Bethesda, MD). For this

analysis, the edge of each ulcer, that is, junction between full thickness skin and the ulcer, was first delineated; then, the computer automatically computed the area of each ulcer as detailed in our previous reports [66,67]. The computed area was then ratioed to the scale of the metric ruler that was photographed with each ulcer. The area of granulation was similarly calculated using the threshold color corresponding to granulation tissue. Thereafter, the normalized rates of healing and granulation were computed from the measurements obtained.

### Statistical Analysis

Descriptive statistics were generated and *t*-tests used to compare the clinical characteristics of the patients as shown in Table 1. Linear regression analysis was used to determine the relationship between the rate of tissue granulation and the rate of healing. Because the data concerning the rates of healing and tissue granulation were not normally distributed, non-parametric ANOVA was used to analyze the effect of treatment, following which Mann–Whitney *U* test was used to pinpoint differences in the rates of healing and granulation of both groups of ulcers at each period. In each case, the level of significance was set at  $P < 0.05$ .

### RESULTS

As shown in Table 1, the clinical characteristics of both groups of patients were similar. There were no statistically significant differences in age ( $P = 0.60$ ), duration of diabetes ( $P = 0.18$ ), duration of ulcer which varied markedly from patient to patient ( $P = 0.23$ ) or initial ulcer sizes which also varied significantly from patient to patient, more so in group two ( $P = 0.24$ ). In addition to diabetes, patients had other co-morbidities; including high blood pressure (HBP) (four patients), chronic venous insufficiency (CVI) (five patients) and HPB combined with CVI

**TABLE 1. Clinical Characteristics of the Patients by Group**

Characteristic	Group one	Group two	Statistical comment
Age (years)			
Mean $\pm$ SD	63.4 $\pm$ 11.26	66.3 $\pm$ 14.73	$t = 0.44$ ; $P = 0.67$
Median	67.0	63	None
Range	47–77	50–87	None
Duration of diabetes (years)			
Mean $\pm$ SD	11.3 $\pm$ 7.40	11.4 $\pm$ 11.39	$t = 0.031$ ; $P = 0.98$
Median	10	12	None
Range	1.3–25	1.3–32	None
Number of patients	7	7	None
Number of ulcers	10	13	None
Duration of ulcers (months)			
Mean $\pm$ SE (months)	28.10 $\pm$ 23.6	95.5 $\pm$ 33.0	$t = 1.01$ ; $P = 0.23$
Median (months)	4.0	10.0	None
Range (months)	1–240	4–240	None
Initial ulcer size in $\text{cm}^2$			
Mean $\pm$ SD	3.8 $\pm$ 4.13	11.8 $\pm$ 20.46	$t = 1.21$ ; $P = 0.24$
Median ( $\text{cm}^2$ )	2.25	4.4	None
Range ( $\text{cm}^2$ )	1–8.3	1–75.4	None

**TABLE 2. Location of Ulcers in Both Groups of Patients**

Group one ulcers	Group two ulcers
(1) Plantar surface of the left foot	(1) Plantar surface of the right halux
(2) Medial area of the right lower leg	(2) Plantar surface of the left halux
(3) Site of amputation, left metatarsals	(3) Medial area of the left lower leg
(4) Left lateral malleolus	(4) Anterior area of the left lower leg
(5) Anterior surface right lower leg	(5) Lateral area of the left lower leg
(6) Anterior surface upper right leg	(6) Lateral area of the left lower leg
(7) Left calcaneum	(7) Amputation site left lower leg
(8) Anterio-lateral area of the left lower leg	(8) Medial area of the right lower leg
(9) Anterio-lateral area of the right lower leg	(9) Anterior area of the right lower leg
(10) Lateral surface of the left lower leg	(10) Lateral area of the right lower leg
	(11) Posterior-lateral area of the right leg
	(12) Right Achilles tendon
	(13) Posterior area of the right lower leg

(five patients). The diabetes and HBP were each controlled with medication.

Ulcers were located mostly in the lower leg and the plantar surfaces of the feet as summarized in Table 2. The clinical signs associated with the ulcers at the beginning of treatment were: hyperchromia (60%), lipodermatosclerosis (10%), varicosity (50%), edema (10%), pruritus (10%), eczema (30%), and pain (50%). Regression analysis showed a strong positive relationship between tissue granulation and ulcer healing ( $r^2 = 0.97$ ;  $P < 0.0001$ ), indicating that either variable predictably measured the outcome of treatment. At each of 15, 30, 45, 60, 75, and 90 days of healing, mean ulcer healing and granulation rates were significantly higher in group two than “placebo” group one (Table 3 and Figs. 2 and 3).

While group two ulcers healed rapidly during the initial 30 days of treatment, group one ulcers worsened; resulting in 56% more granulation and 79.2% greater healing in group two, and suggesting that both groups of ulcers, which were not responding to other forms of treatment, would have deteriorated progressively in the absence of intervention (Table 3 and Fig. 2). Throughout the 90-day period, group two ulcers maintained significantly higher rates of granulation and healing over group one ulcers; with 48–68.4% more granulation and 47.5–79.2% greater

healing (Table 3). At the 90-day mark, 58.3% of group two ulcers had healed fully and overall, 75% had achieved 90–100% healing (Fig. 3). In contrast, only one group one ulcer healed fully by day 90; no other ulcer in this group attained  $\geq 90\%$  healing at any time.

The response to “placebo” treatment, which was negative at first, turned slowly but steadily positive after the first 45 days of treatment (Fig. 2), suggesting that the small amount of light emitted by the “placebo” probe had a cumulative effect that eventually reversed the trend toward worsening of the ulcers. This response varied markedly from one probe one treated ulcer to another, as evidenced by the higher standard deviations of their healing rates at each interval (Fig. 2a). It is conceivable that the “placebo” dose met the threshold needed to stimulate healing in some of the ulcers—something that was not anticipated at the beginning of the study.

Group two patients began to report pain relief as early as 1 week of treatment, even though pain relief was never a focus of our study and objective measurement of their ulcers had not yet shown evidence of improved healing. No patient in group one reported early relief from pain. Furthermore, neither amputation nor any other surgical measure was required by any of the patients and no adverse effects of any kind were reported as a result of treatment.

**TABLE 3. Normalized Mean Ulcer Granulation and Healing Rates by Group**

Time (days)	Ulcer granulation rate			Ulcer healing rate		
	Group one (mean $\pm$ SE)	Group two (mean $\pm$ SE)	Statistical comment	Group one (mean $\pm$ SE)	Group two (mean $\pm$ SE)	Statistical comment
0	0	0	None	0	0	None
15	$-8.9 \pm 9.35$	$39.6 \pm 6.30$	$P = 0.0006$	$-8.9 \pm 9.35$	$44.1 \pm 8.15$	$P < 0.0002$
30	$-2.3 \pm 9.64$	$58.6 \pm 6.62$	$P = 0.0001$	$-12.3 \pm 20.23$	$66.9 \pm 6.67$	$P = 0.0002$
45	$1.0 \pm 12.24$	$65.4 \pm 6.77$	$P = 0.0005$	$0.09 \pm 30.7$	$79.3 \pm 6.36$	$P < 0.003$
60	$10.8 \pm 12.42$	$79.2 \pm 7.00$	$P = 0.0003$	$22.9 \pm 33.39$	$82.7 \pm 5.79$	$P < 0.005$
75	$21.9 \pm 11.34$	$80.7 \pm 6.71$	$P = 0.0006$	$35.9 \pm 32.00$	$85.8 \pm 5.62$	$P < 0.02$
90	$30.8 \pm 11.24$	$87.0 \pm 4.96$	$P = 0.0004$	$43.3 \pm 34.52$	$90.8 \pm 4.94$	$P < 0.02$

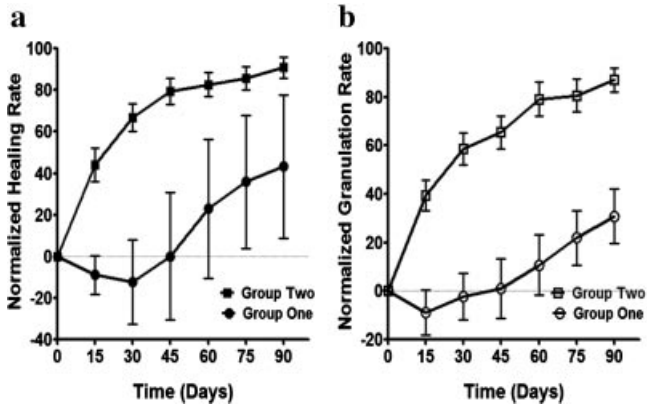


Fig. 2. Graphs showing normalized rates of healing (a) and tissue granulation (b) over time. In figure 2a, black square = healing rate of group two treated ulcers; black circle = healing rate of placebo treated ulcers. In figure 2b, white square = granulation rate of group two treated ulcers; white circle = granulation rate of placebo treated ulcers.

**DISCUSSION**

The superior rates of healing and granulation of ulcers treated with combined 660 and 890 nm light cannot be attributed to possible differences in the clinical characteristics of patients, since patients were randomly assigned to groups and the two groups had statistically similar characteristics. Moreover, the same inclusion and exclusion criteria were used to admit both groups of patients into the study.

Tissue granulation is rarely measured or reported in the literature. Because our software allowed us to measure this variable, we were interested in exploring the relationship between the rate of tissue granulation and wound closure rate, a commonly used measure of tissue repair. The strong positive correlation between the rate of tissue granulation and the rate of healing suggests that either variable would have been sufficient to determine the outcome of treatment.

The response of “placebo” treated ulcers varied markedly and was generally negative during the initial 45 days of treatment, but became slowly and steadily positive during the latter half of the 90-day intervention. Since the ulcers studied had been non-responsive to treatment, it is conceivable that, overall, the ulcers would have deteriorated progressively in the absence of intervention. Thus, the initial negative response followed by slow positive healing after 45 days, suggests that the small amount of visible light emitted by the “placebo” probe had a cumulative effect that eventually reversed the trend toward worsening of the ulcers; resulting in modest improvements in healing over time. The higher standard deviations associated with their mean healing rates reflect the variability in the responses of individual ulcers to “placebo” treatment. It is conceivable that the “placebo” dose met the threshold needed to stimulate healing in some but not all of the ulcers. For example, one “placebo” treated ulcer healed fully within 60 days. Nonetheless, the superiority of full treatment with combined 660 and 890 nm light remained pronounced throughout, and is further evidenced by the subjective remarks volunteered by our patients after the initial 1 week of treatment. Group two

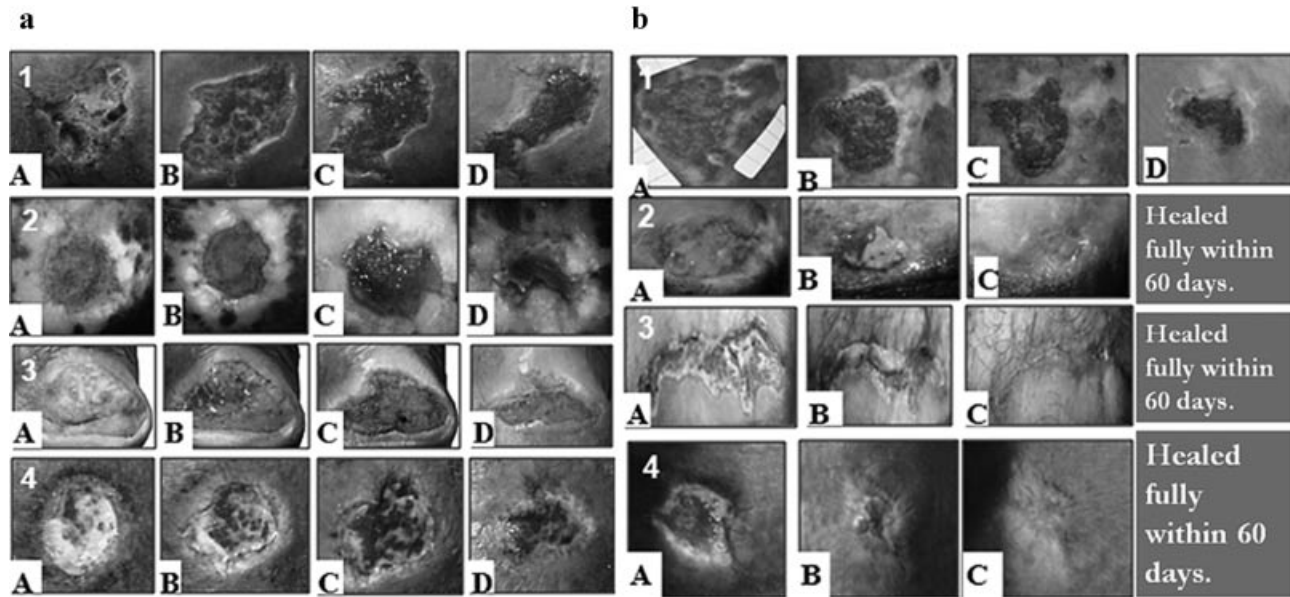


Fig. 3. Representative photographs showing placebo and real treatment ulcers. Figure 3a shows four placebo treated ulcers, while figure 3b shows four real treatment ulcers. Photos labeled “A” represent initial ulcer sizes; B, C, and D represent ulcer sizes at days 30, 60, and 90, respectively.

patients reported feeling less pain and being able to sleep better at night very early in the study, an observation that increased progressively with time. This subjective finding is consistent with other reports which indicate that phototherapy relieves pain and accelerates the resolution of inflammation [68].

That 58.3% of the ulcers treated with probe two healed fully and 75% achieved  $\geq 90\%$  healing within 90 days of treatment is consistent with reports which indicate that 50–90% of diabetic ulcers respond positively to phototherapy, depending on treatment parameters [5,69,70]. In their pioneering report, Mester et al. [5] found that 92.4% of the 1,120 cases treated with  $4.0 \text{ J cm}^{-2}$  694 nm red light either improved or healed fully. Complete healing was achieved in 78.1% of the cases and 80% of the 15 cases classified as “Diabetic lipodystrophy” healed completely, but there was no control group in the cohort [5]. Similarly, Kleinman et al. [69] achieved full healing in 87.5% of recalcitrant leg ulcers using 785 nm light or a combination of 632.8 and 765 nm light. While Lichtenstein and Morag [70], who treated 62 patients with healing-resistant venous ulcers, demonstrated full healing in 85.5% of the cases following irradiation with either 632.8 or 830 nm light. These studies lacked control groups and were carried out over longer periods than ours; but consistent with our finding, a low amount of energy density was used to achieve the results and no adverse effects were reported in any of the studies [5,69,70].

Similarly, in a study of 20 patients with 20 ulcers that were minimally responsive to conventional treatment after a median period of 34 weeks, Schindl et al. [71] found that treatment with  $30 \text{ J cm}^{-2}$  energy density of He-Ne laser effectively advanced healing; resulting in complete epithelialization of the ulcers, including sores occasioned by “radio damage,” diabetes, arterial insufficiency, and autoimmune vasculitis. Similar to our findings, neither amputation nor any other surgical measure was necessary and no adverse effects of any kind were noted throughout the study [71]. Studies of experimentally simulated ulcer infections in rats provide further evidence that phototherapy promotes healing of wounds that do not respond to treatment otherwise [11]. As demonstrated by Lee et al. [1] treatment of such ulcers with 904 nm light reduces swelling and promotes healing of experimentally infected wounds. These observations are consistent with our previous report in which we showed that photostimulation with combined 660 and 890 nm light also promotes healing of chronic venous ulcers [67].

How light promotes tissue repair is not fully known, but as detailed in the introduction, treatment with light has been repeatedly shown to promote fibroblast proliferation [34–44], collagen synthesis and related granulation tissue formation [45–48], as well as the underlying metabolic processes that enhance collagen formation [49], ATP synthesis and lymphocytic action [5,50–51]. Furthermore, phototherapy has been shown to promote blood flow and the formation of new blood vessels in experimental animal models of injury and repair [72]. More recently, Samoilova et al. [73] showed that irradiation with a broad

spectrum Q-light ( $\lambda = 385\text{--}750 \text{ nm}$ ), using  $40 \text{ mW cm}^{-2}$  irradiance and  $12 \text{ J cm}^{-2}$  fluence, promotes blood flow in the irradiated hands of human volunteers. A 32% increase in blood flow was recorded on the average; reaching 45% within 20 minutes of exposure. Moreover, the effect was systemic, given the increases in blood flow recorded in the non-irradiated contralateral hands. Administration of N-monomethyl-L-arginine, a nitric oxide synthesis (NOS) inhibitor, blocked the rise in blood flow, suggesting that the recorded increase in skin microcirculation was due to activation of NO synthesis [73].

Further evidence that phototherapy promotes microcirculation comes from a double blind placebo controlled study of 30 patients with diabetic microangiopathy [32]. A single transcutaneous irradiation of the forefoot region of the patients using athermal  $30 \text{ J cm}^{-2}$  energy density was shown to cause a statistically significant rise in skin temperature as measured by infrared thermography; suggesting increased blood flow in the region [32]. These findings suggest that increased blood flow to photo-irradiated ulcers is, at least, a possible mechanism underlying our positive results.

Even though others have offered detailed comments, analysis and meta-analysis of the literature [74–82], the strong positive findings of our study warrant further discussion of the clinical value of phototherapy, given the widespread perception that the literature is replete with contradictory data. For example, treatment of nine patients with 12 “minor postsurgical wounds” using  $300 \text{ mW cm}^{-2}$  irradiance and  $9 \text{ J cm}^{-2}$  fluence of 830 nm light was reported to be ineffective in promoting wound closure or reducing the pain caused by the incisions [83]. Under normal circumstances, minor surgical wounds should heal within days even with regular dressing, making it unnecessary to treat with light. Thus, barring infection, treatment with light would not make a difference in the healing rates of such minor wounds. This observation is consistent with our previous finding that small-sized ulcers or minor wounds have a tendency to heal properly regardless of treatment [67], a finding that is consistent with the literature [71]. However, that minor surgical wounds may require a different treatment phototherapy protocol cannot be ruled out, particularly in view of the finding that they respond positively when treated only once with  $1.3 \text{ J cm}^{-2}$  of 830 nm light [84].

In our preliminary studies, we found that wound debridement complicated regular measurement of ulcer sizes because of the tendency to impair the margins of some but not all of the ulcers. For these reasons, ulcers were cleaned without surgical debridement as detailed in the methods section. This experience enables us to comment on the findings of Allendorf et al. [59] who reported that treatment with He-Ne laser did not produce any measurable benefit on wound healing in a study in which debridement of eschars was done every day. The negative outcome of their study may be ascribed to the unpredictable effect of daily debridement and removal of eschars. Hence it should not come as a surprise that they could not detect any measurable benefit of phototherapy.

Our present study represents a pioneering effort to determine the true effect of phototherapy on chronic slow- or non-healing diabetic ulcers in an experimentally controlled manner. Although our results are highly encouraging, our rigid inclusion and exclusion criteria restricted our sample size; limiting our ability to generalize our findings. Moreover, we could not measure or determine ulcer volume even though ulcers were digitally photographed and digitally computed to advance precise computation of ulcer sizes. This limitation made it impossible to determine the effect of phototherapy on ulcer volume, a measure that—at times—differs from ulcer size. Furthermore, we could not totally eliminate light therapy from the “placebo” treatment. Doing so would have made it impossible to “blind” the patient and the research team. Moreover, it would have significantly weakened objectivity. As it turned out, even the small amount of visible 660 nm light applied to group one ulcers appears to have had some unanticipated positive healing effect. Regardless, the positive effect of the higher energy combined 660 and 890 nm light remained pronounced all through.

## CONCLUSION

Our results mandate the conclusion that the combination of 660 and 890 nm light used in this study promotes tissue granulation and rapid healing of diabetic ulcers that failed to respond to other forms of treatment. Further study with a larger sample size is warranted.

## ACKNOWLEDGMENTS

We thank Dynatronics Corporation, Salt Lake City, UT, USA, for donating the Solaris<sup>®</sup> light therapy device used in this study, and Precision Garage, Faculty of Medicine, University of São Paulo, Ribeirão Preto, Brazil for customizing the device used to standardize digital photography. We acknowledge the grant support provided by CNPq, FAEPA-HCFMRP-USP, Sao Paulo, Brazil, and the assistance of Professor Gil Almeida in planning the study.

## REFERENCES

- Sommer AP, Pinheiro ALB, Mester AR, Franke RP, Whelan HT. Biostimulatory windows in low-intensity laser activation: Lasers, scanners, and NASA's light emitting diode array system. *J Clin Laser Med Surg* 2001;19:29–33.
- Enwemeka CS. Light is light. *Photomed Laser Surg* 2005;23:159–160.
- Powell MW, Carnegie DE, Burke TJ. Reversal of diabetic peripheral neuropathy and new wound incidence: The role of MIRE. *Adv Skin Wound care* 2004;17:143–147.
- DeLellis SL, Carnegie DH, Burke TJ. Improved sensitivity in patients with peripheral neuropathy. Effects of monochromatic infrared photo energy. *J Am Podiatr Med Assoc* 2005;95:143–147.
- Mester E, Mester AF, Mester A. The biomedical effects of laser application. *Lasers Surg Med* 1985;5:31–39.
- Conlan MJ, Rapley JW, Cobb CM. Biostimulation of wound healing by low-energy laser irradiation. A review. *J Clin Periodont* 1996;23:492–496.
- Yu W, Naim JO, Lanzafame RJ. Effects of photostimulation on wound healing in diabetic mice. *Lasers Surg Med* 1997;20:56–63.
- Braverman B, McCarthy RJ, Ivankovich AD, Forde DE, Overfield M, Bapna MS. Effect of helium-neon and infrared laser irradiation on wound healing in rabbits. *Lasers Surg Med* 1989;9:50–58.
- Longo L, Evangelista S, Tinacci G, Sesti AG. Effect of diode-laser silver arsenide-aluminum (Ga-Al-As) 904 nm on healing of experimental wounds. *Lasers Surg Med* 1987;7:444–447.
- Al-Watban FAH, Zhang XY. Stimulative and inhibitory effects of low incident levels of argon laser energy on wound healing. *Laser Ther* 1995;7:11–18.
- Lee P, Kim K, Kim K. Effects of low incident energy levels of infrared laser irradiation on healing of infected open skin wounds in rats. *Laser Ther* 1993;5:59–64.
- Ghamsari SM, Taguchi K, Abe N, Acorda JA, Sato M, Yamada H. Evaluation of low level laser therapy on primary healing of experimentally induced full thickness teat wounds in dairy cattle. *Vet Surg* 1997;26:114–120.
- Akai M, Usuba M, Maeshima T, Shirasaki Y, Yasuoka S. Laser's effect on bone and cartilage change induced by joint immobilization: An experiment with animal model. *Lasers Surg Med* 1997;21:480–484.
- Bayat M, Delbari A, Almaseyeh MA, Sadeghi Y, Bayat M, Rezaie F. Low-level Laser therapy improves early healing of medial collateral ligament injuries in rats. *Photomed Laser Surg* 2005;23(6):556–560.
- Guzzaredla GA, Torriceli P, Rocca M, Tigani D, Brodano GB, Ferrari D, Fini M, Giardino R. Assessment of low-power laser biostimulation on chondral lesions. An in vivo experimental study. *Art Cells Blood Subs Immob Biotech* 2000;28(5):441–449.
- Guzzaredla GA, Torriceli P, Fini M, Martini L, Morrone G, Giardino R. Low-power diode laser stimulation of surgical osteochondral defects. Results after 24 weeks. *Art Cells Blood Subs Immob Biotech* 2001;29(3):235–244.
- Enwemeka CS. Laser photostimulation. *Clin Manage* 1990;10:24–29.
- Reddy GK, Stehno-Bittel L, Enwemeka CS. Laser photostimulation of collagen production in healing rabbit Achilles tendons. *Lasers Surg Med* 1998;22:281–287.
- Enwemeka CS, Cohen E, Duswalt EP, Weber DM. The biomechanical effects of Ga-As laser photostimulation on tendon healing. *Laser Ther* 1995;6:181–188.
- Enwemeka CS. Ultrastructural morphology of membrane-bound intracytoplasmic collagen fibrils in tendon fibroblasts exposed to He:Ne laser beam. *Tissue Cell* 1992;24:511–523.
- Ozawa Y, Shimizu N, Kariya G, Abiko Y. Low-energy laser irradiation stimulates bone nodule formation at early stages of cell culture in rat calvarial cells. *Bone* 1998;22:347–354.
- Houghton PE, Brown JL. Effect of low level laser on healing in wounded fetal mouse limbs. *Laser Ther* 1999;11:54–69.
- Luger EJ, Wollman Y, Kogan G, Dekel S. Effect of low-power laser irradiation on the mechanical properties of bone fracture healing in rats. *Laser Surg Med* 1998;22:97–102.
- Ozawa YSN, Kariya G, Abiko Y. Low-energy laser irradiation stimulates bone nodule formation at early stages of cell culture in rat calvarial cells. *Bone* 1998;22(4):347–354.
- Guzzarella GA, Porriceli P, Aldini NN, Giardino R. Laser technology in orthopedics: Preliminary study on low-power laser therapy to improve the bone-biomaterial interface. *Int J Artif Organs* 2001;24(12):898–902.
- Morrone GGG, Torriceli P, Rocca M, Tigani D, Brodano GB, Fini M, Giardini R. Osteochondral lesion repair of the knee in the rabbit after low-power diode Ga-Al-As laser biostimulation: An experimental study. *Art Cells Blood Subs Immob Biotech* 2000;28(4):321–336.
- Torriceli PGG, Fini M, Guzzardella GA, Morrone G, Carpi A, Giardini R. Laser biostimulation of cartilage: In vitro evaluation. *Biomed Pharmacother* 2001;55:117–120.
- Morrone GGG, Guzzardella GA, Tigani D, Torriceli P, Fini M, Giardini R. Biostimulation of human chondrocytes with Ga-Al-As diode laser: In vitro Research. *Art Cells Blood Subs Immob Biotech* 2000;28:193–201.
- Morrone GGG, Torriceli P, Fini M, Giardini R. In vitro experimental research of rabbit chondrocytes with diode

- laser GA-Al-As: A preliminary study. *Art Cells Blood Subs Immob Biotech* 1998;26(4):437–439.
30. Schindl A, Schindl M, Schindl L. Successful treatment of a persistent radiation ulcer by low power laser therapy. *J Am Acad Dermatol* 1997;37:646–648.
  31. Schindl A, Schindl M, Schindl L. Phototherapy with low intensity laser irradiation for a chronic radiation ulcer in a patient with lupus erythematosus and diabetes mellitus [letter]. *Br J Dermatol* 1997;137:840–841.
  32. Schindl A, Schindl M, Schon H, Knobler R, Havelec L, Schindl L. Low-intensity laser irradiation improves skin circulation in patients with diabetic microangiopathy. *Diabetes Care* 1998;21:580–584.
  33. Lundeberg T, Malm M. Low-power HeNe laser treatment of venous leg ulcers. *Annals Plastic Surg* 1991;27:537–539.
  34. Al-Watban FAH, Zhang XY. Comparison of the effects of laser therapy on wound healing using different laser wavelengths. *Laser Ther* 1996;8:127–135.
  35. Al-Watban FAH, Zhang XY. Comparison of wound healing process using argon and krypton lasers. *J Clin Laser Med Surg* 1997;15:209–215.
  36. Braverman B, McCarthy RJ, Ivankovich AD, Forde DE, Overfield M, Bapna MS. Effect of helium-neon and infrared laser irradiation of wound healing in rabbits. *Lasers Surg Med* 1989;9:50–58.
  37. Bouma MG, Buurman WA, van den Wildenberg FAJM. Low energy laser irradiation fails to modulate the inflammatory function of human monocytes and endothelial cells. *Lasers Surg Med* 1996;19:207–215.
  38. Allendorf JDF, Bessler M, Huang J, Kayton ML, Laird D, Nowygrod R, Treat MR. Helium-neon laser irradiation at fluences of 1, 2 and 4 J/cm<sup>2</sup> failed to accelerated wound healing as assessed by both wound contracture rate and tensile strength. *Lasers Surg Med* 1997;20:340–345.
  39. El Sayed SO, Dyson M. Effect of laser pulse repetition rate and pulse duration on mast cell number and degranulation. *Lasers Surg Med* 1996;19:433–437.
  40. El Sayed SO, Dyson M. Comparison of the effect of multi-wavelength light produced by a cluster of semiconductor diodes and of each individual diode on mast cell number and degranulation in intact and injured skin. *Lasers Surg Med* 1990;10:559–568.
  41. Dyson M, Young S. Effect of laser therapy on wound contraction and cellularity in mice. *Lasers Med Sci* 1986;1:125–130.
  42. Shiroto C, Sugawara K, Kumae T, Ono Y, Sasaki M, Ohshiro T. Effect of diode laser radiation in vitro on activity of human neutrophils. *Laser Ther* 1989;1:135–140.
  43. Young S, Bolton P, Dyson M, Harvey W, Diamantopoulos C. Macrophage responsiveness to light therapy. *Lasers Surg Med* 1989;9:497–505.
  44. Haas AF, Isseroff R, Wheeland RG, Rood PA, Graves PJ. Low-energy helium-neon laser irradiation increases the motility of cultured human keratinocytes. *J Invest Dermatol* 1990;94:822–826.
  45. Abergel RP, Lyons RF, Castel JC, Dwyer RM, Uitto J. Biostimulation of wound healing by lasers: Experimental approaches in animal models and in fibroblast cultures. *J Dermatol Surg Oncol* 1987;13:127–133.
  46. Graham DJ, Alexander JJ. The effects of argon laser on bovine aortic endothelial and smooth muscle cell proliferation and collagen production. *Curr Surg* 1990;47:27–30.
  47. Pogrel MA, Chen JW, Zhang K. Effects of low-energy gallium-aluminum-arsenide laser irradiation on cultured fibroblasts and keratinocytes. *Lasers Surg Med* 1997;20:426–432.
  48. Steinlechner C, Dyson M. The effects of low level laser therapy on the proliferation of keratinocytes. *Laser Ther* 1993;5:65–73.
  49. Saperia D, Glassberg E, Lyons RF, Abergel RP, Baneux P, Castel JC, Dwyer RM, Uitto J. Demonstration of elevated type I and type III procollagen mRNA levels in cutaneous wounds treated with helium-neon laser. Proposed mechanism for enhanced wound healing. *Biochem Biophys Res Commun* 1986;138:1123–1128.
  50. Young S, Bolton P, Dyson M, Harvey W, Diamantopoulos C. Macrophage responsiveness to light therapy. *Lasers Surg Med* 1989;9:497–505.
  51. Passarella S, Casamassima E, Molinari S, Pastore D, Quagliariello E, Catalano IM, Cingolani A. Increase of proton electrochemical potential and ATP synthesis in rat liver mitochondria irradiated in vitro by helium-neon laser. *FEBS Lett* 1984;175:95–99.
  52. Basford JR, Hallman HO, Sheffield CG, Mackey GL. Comparison of cold-quartz ultraviolet, low-energy laser, and occlusion in wound healing in a swine model. *Arch Phys Med Rehabil* 1986;67:151–154.
  53. Nussbaum EL, Biemann I, Mustard B. Comparison of ultrasound/ultraviolet-C and laser for treatment of pressure ulcers in patients with spinal cord injury. *Phys Ther* 1994;74:812–823.
  54. Basford JR. Laser therapy: Scientific basis and clinical role. *Lasers Ortho Surg* 1993;16(5):541–547.
  55. McMeeken J, Stillman B. Perceptions of the efficacy of laser therapy. *Aust Physiotherapy* 1993;39:101–106.
  56. Basford JR. Low-energy laser therapy: Controversies and new research findings. *Lasers Surg Med* 1989;9:1–5.
  57. Bouma MG, Buurman WA, van den Wildenberg FAJM. Low energy laser irradiation fails to modulate the inflammatory function of human monocytes and endothelial cells. *Lasers Surg Med* 1996;19:207–215.
  58. Hallman HO, Basford JR, O'Brien JF, Cummins LA. Does low-energy helium-neon laser irradiation alter "in vitro" replication of human fibroblasts? *Lasers Surg Med* 1988;8:125–129.
  59. Allendorf JDF, Bessler M, Huang J, Kayton ML, Laird D, Nowygrod R, Treat MR. Helium-neon laser irradiation at fluences of 1, 2 and 4 J/cm<sup>2</sup> failed to accelerated wound healing as assessed by both wound contracture rate and tensile strength. *Lasers Surg Med* 1997;20:340–345.
  60. Neiburger EJ. Rapid healing of gingival incisions by the helium-neon diode laser. *J Mass Dent Soc* 1999;48:8–13.
  61. National Center for Health Statistics, Center for Disease Control and Prevention, National Health and Nutrition Examination Survey (NHANES). <http://www.cdc.gov/nchs/nhanes/htm>.
  62. Phillips TJ. Chronic cutaneous ulcers: Etiology and epidemiology. *J Invest Dermatol* 1994;102:38s–41s.
  63. Nelzen O, Bergqvist D, Lindhagen A. High prevalence of diabetes in chronic leg ulcer patients: A cross-sectional population study. *Diabet Med* 1993;10:345–350.
  64. Pecoraro RE, Reiber GE, Burgess EM. Pathways to diabetic limb amputation. Basis for prevention. *Diabetes Care* 1990;13:513–521.
  65. Harding KG, Morris HL, Patel GK. Science, medicine and the future: Healing chronic wounds. *Br Med J* 2002;324:160–163.
  66. Minatel DG, França SC, Enwemeka CS, Frade MAC. Phototherapy (LEDs 660/890 nm) in the treatment of leg ulcers in diabetic patients: Case study. *An Bras Dermatol* 2009;84(3):279–283.
  67. Caetano KS, Frade MAC, Minatel DG, Santana LA, Enwemeka CS. Phototherapy improves healing of chronic venous ulcers. *Photomed Laser Surg* 2009;27:111–118.
  68. Gur A, Sarac AJ, Cevik R, Altindag O, Sarac S. Efficacy of 904 nm gallium arsenide low level laser therapy in the management of chronic myofascial pain in the neck: A double-blind and randomize-controlled trial. *Lasers Surg Med* 2004;35:229–235.
  69. Kleinman Y, Simmer S, Braksma Y, Morag B, Lichtenstein D. Low level laser therapy in patients with venous ulcers: Early and long term outcomes. *Laser Ther* 1996;8:205–208.
  70. Lichtenstein D, Morag B. Low level laser therapy in ambulatory patients with venous stasis ulcers. *Laser Ther* 1998;11(2):71–78.
  71. Schindl M, Kerschman K, Schindl A, Schön H, Heinzl H, Schindl L. Induction of complete wound healing in recalcitrant ulcers by low-intensity laser irradiation depends on ulcer cause and size. *Photodermatol Photoimmunol Photomed* 1999;15:18–21.
  72. Revazova E, Sorokina Y, Bryzgalov I, Sebastian J, Keller G, Ivanov A, Watson J. The use of low-power laser irradiation

- for faster vascularization of tissue transplants. *Bull Exp Biol Med* 2001;132:873–876.
73. Samoilova KA, Zhevago NA, Petrishchev NN, Zimin AA. Role of nitric oxide in the visible light-induced rapid increase of human skin microcirculation at the local and systemic levels: II. Healthy volunteers. *Photomed Laser Surg* 2008;26:443–449.
  74. Schindl A, Schindl M, Schön H, Knobler R, Havelec L, Schindl L. Low-intensity laser irradiation improves skin circulation in patients with diabetic microangiopathy. *Diabetes Care* 1998;21:580–584.
  75. Bjordal JM, Lopes-Martin RA, Klovning A. Is quality control of Cochran reviews in controversial areas sufficient? *J Altern Complement Med* 2006;12(2):181–183.
  76. Lanzafame RJ. Pure or tarnished: Are systematic reviews blind or biased? *Photomed Laser Surg* 2005;23(5):451–452.
  77. Enwemeka CS, Parker JC, Dowdy DS, Harkness EE, Sanford LE, Woodruff LD. The effect of laser phototherapy on tissue repair and pain control: A meta-analysis of the literature. *Photomed Laser Surg* 2004;22:323–329.
  78. Woodruff LD, Bounkeo JM, Brannon WM, Dawes Jr. KS, Barham CD, Waddell DL, Enwemeka CS. The efficacy of laser therapy in wound repair: A meta-analysis of the literature. *Photomed Laser Surg* 2004;22:241–247.
  79. Sobanko JF, Alster TS. Efficacy of low-level laser therapy for chronic cutaneous ulceration in humans: A review and discussion. *Dermatol Surg* 2008;34:991–1000.
  80. Hawkins D, Houreld N, Abrahamse H. Low level laser therapy (LLLT) as an effective therapeutic modality for delayed wound healing. *Ann NY Acad Sci* 2005;1056:486–493.
  81. Posten W, Wrone DA, Dover JS, Arndt KA, Silapunt S, Alam M. Low-level laser therapy for wound healing: Mechanism and efficacy. *Dermatol Surg* 2005;31:334–340.
  82. Franek A, Król P, Kucharzewski M. Does low output laser stimulation enhance the healing of crural ulcerations? Some critical remarks. *Med Eng Phys* 2002;24:607–615.
  83. Lagan KM, Clements BA, McDonough S, Baxter GD. Low intensity laser therapy (830 nm) in the management of minor postsurgical wounds: A controlled clinical study. *Lasers Surg Med* 2001;28:27–32.
  84. Rezende SB, Ribeiro MS, Núñez SC, Garcia VG, Maldonado EP. Effects of a single near-infrared laser treatment on cutaneous wound healing: Biometrical and histological study in rats. *J Photochem Photobiol B* 2007;87:145–153.